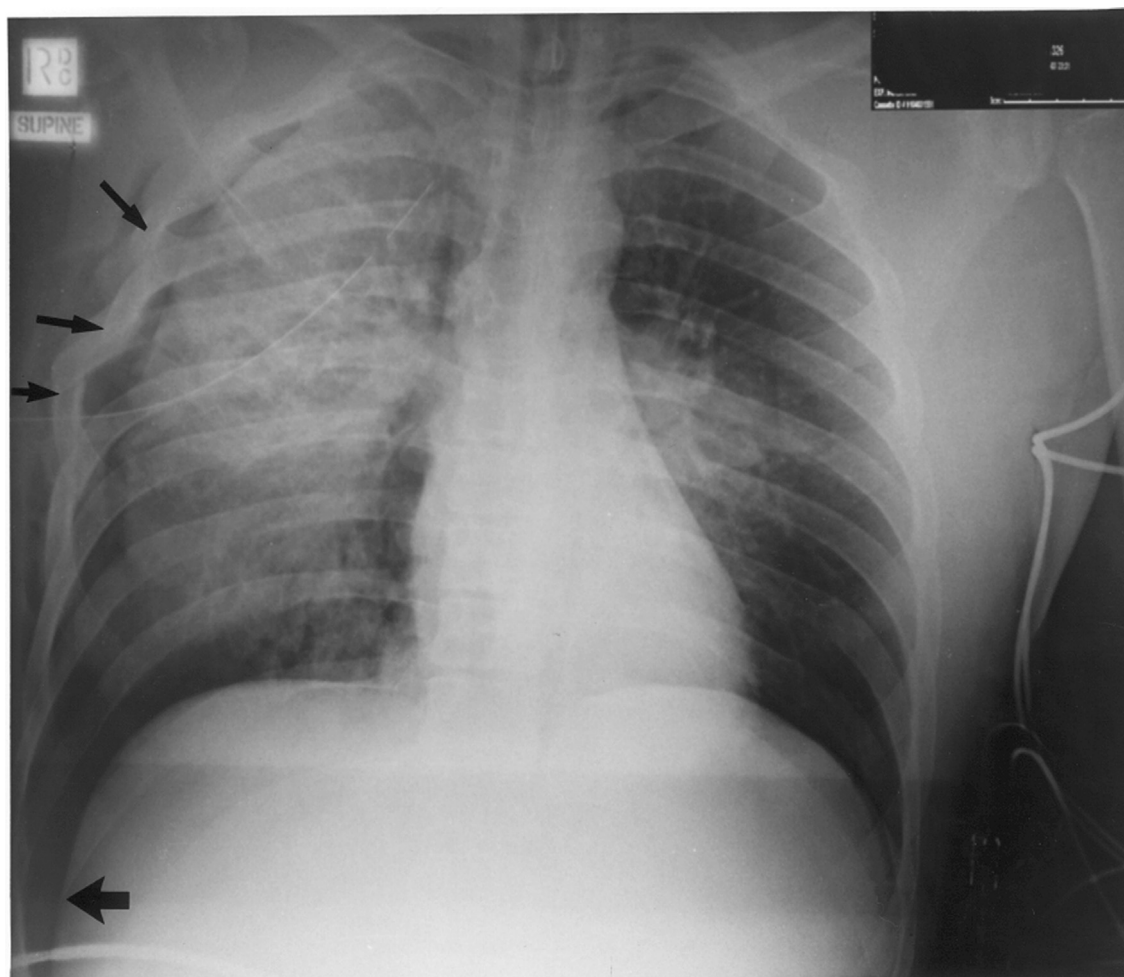




Chest x-ray quiz

Answer and discussion



You should note:

1. Multiple right-sided rib fractures and surgical emphysema (arrowed)
2. Quite marked opacification over the right side, which would be consistent with lung contusion.
3. A deep sulcus sign in the left lateral costophrenic sulcus (arrowed). The deep sulcus sign is a lucent deep costophrenic angle that occurs in supine chest x-rays when a pneumothorax is present. It is worth remembering that a pneumothorax in a patient supine may be very difficult to see hence the importance of the deep sulcus sign.¹
4. Right sided pneumothorax with chest drain.

Reference

- [1] Briggs Greg. Pocket Guide to Chest X-rays. Sydney, New York, Auckland, San Francisco: McGraw-Hill Companies; 2008.