



ELSEVIER

Contents lists available at [ScienceDirect](https://www.sciencedirect.com)

Australian Critical Care

journal homepage: www.elsevier.com/locate/aucc



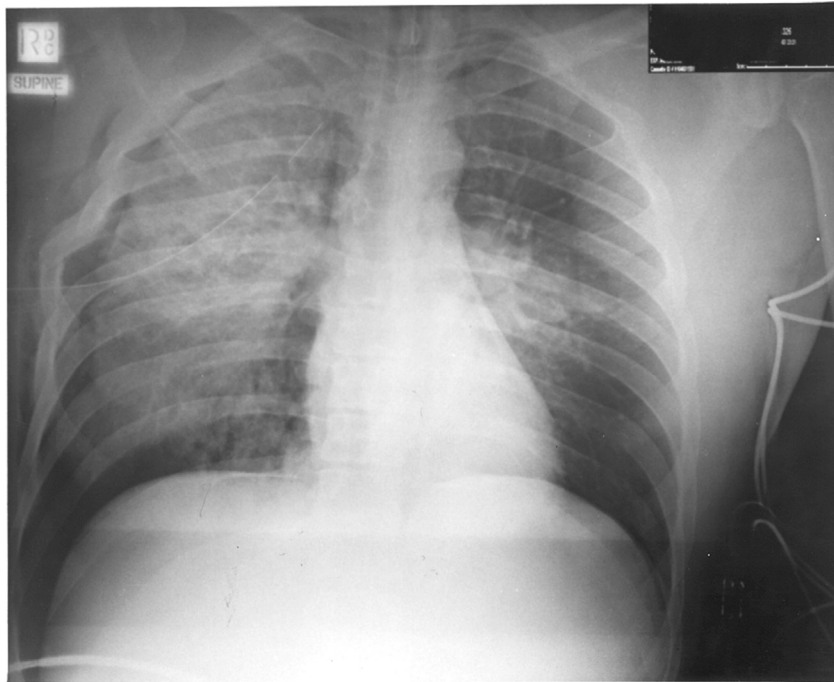
Chest x-ray quiz

Question

Compiled by Marea Reading RN, Consultant Cardiothoracic Nursing Education Sydney NSW

Question

This is an anterior-posterior (AP) supine chest X-ray of a 23-year-old male rider of a motorcycle involved in an accident. What injuries can be noted on the chest X-ray?



Answer and Discussion for the Chest X-ray Quiz is in page 243